

Sleep Disordered Breathing from a Dentistry Point of View

Dr. Horst Kares



Abstract

Sleep Disordered Breathing (SDB) such as snoring and obstructive sleep apnea are symptoms that are currently being diagnosed more and more and that due to their psychological as well as health consequences play a large social and economic role. All the more reason, therefore, to recognize the value of the dentist on an interdisciplinary team and his ability to help in the diagnosis and treatment. After a brief overview on the current state of sleep medicine, different dentistry interventions will be explained and evaluated. Particularly, the „SomnoDent ©“ system, which is noteworthy due to its ease of use, flexibility and acceptance by the patient.

Introduction

Due to continued publicity by the media people are becoming more and more aware of sleep disorders particularly snoring and sleep apnea. Is this because it is a new symptom trend or does it represent an as yet uncovered basis for a variety of diseases? Where does dentistry stand in this area, what role can the dentist play and where can one obtain information on this topic? These are all questions that those of us in dental medicine must ask ourselves. The focus of our efforts is to look at the whole person, who is suffering from these dysfunctions, from within the oral facial sector. Have dentists for a long time not been generally able to correct growth disturbances of the jaw and misalignment of the lower jaw bone up to now? The following pages cover top dental indications in uncomplicated cases from harmless snoring to life threatening obstructive sleep disorders.

Snoring

30% of all adults and 60% of men over 60 years of age tend to make snoring noises (Maurer 1998, Peters 1997). Harmless snoring is at first occasional, for example after alcohol consumption, progresses in a regular fashion and has a low frequency, harmonious character. It becomes a sign of pathology when these snoring noises appear every night and are loud and explosive in character. Snoring can have several causes:

1) restriction of the nasal airways due to polyps or mucous membrane swelling can be the underlying cause particularly in children; **2)** a change in the posterior air space due to the soft palate or uvula, and also **3)** vibrations during the relaxation of the throat muscles in the air current can sometimes serve as release mechanisms for these nightly noises. The most common cause is the tongue that tends to fall posteriorly and can partially block the airways. It is particularly critical to consider loud night time breath noises that are accompanied by lapses in breath sounds. These clinical signs often indicate either obstructive snoring with partial blockage of the airways or obstructive sleep apnea wherein the tongue completely blocks the airways.

Obstructive Sleep Apnea Syndrome

Studies indicate that the prevalence of obstructive sleep apnea syndrome (OSAS) is between 2-10% of the population (Peter 1991, Peters 1997). The term apnea comes from the Greek „Apnoi“ meaning calm. Sleep apnea refers to a sleep related breath interruption of at least 10 seconds. Sleep hypopnea refers to a decrease in breath amplitude/frequency with a subsequent decrease in oxygen saturation of at least 3% or a wake reaction (Arousal, ASDA 1992). Another type of breath disturbance without snoring is the Upper Airway Resistance Syndrome (UARS). In this condition a crescendo like increase in airway resistance in the upper airways is accompanied by an increase in the negative intrathoracic pressure amplitude leading to arousal with disturbance of the sleep structure and increased daytime sleepiness (Guilleminaut 1982 u. 1995).

In OSAS the tongue base partially (hypopnea) or completely (apnea) closes the pharynx so that breathing is interrupted for a few seconds or longer although strained chest and diaphragm breathing is present and demonstrable. No other dysfunctions are present other than this breathing resistance, which is indicative of a central sleep apnea syndrome in other words with a dysfunction in the respiratory center of the medulla-oblongata (Cheynes-Stokes respiration). Using the apnea-hypopnea index (AHI) the central obstructive and mixed apnea and hypopnea phases can be tallied and separated from sleep duration. This value is a marker for the degree of severity of OSAS. The sleep apnea syndrome is considered, according to the ICSD classification system, as a dyssomnia and accordingly as a medically significant sleep disturbance. An AHI of over 20 is in any case significant and requires treatment. In these

phases the blood oxygen concentration falls considerably and in many cases can lead to clinical symptoms such as: sleep loss, morning headache, hypertonia, acidic belching with throat burning, impotence, negative changes in personality, reduction in intellectual capacity as well as other symptoms. Because of an increased mortality due to circulatory heart disease as well as the number of associated auto accidents this illness has an impact on health politics (Cassel 1993, Konermann 1995, Rasche 1995, Waller 1989). Frequently, overweight, middle-aged men are of particular concern, but women can not be excluded and neither can children with marked retrognathia (Jamieson 1986).

Diagnosing Sleep Disordered Breathing

Ambulatory screening of SDB can be carried out in every medical or dental practice using standardized questionnaires and easy 1-2 channel measurement tools (Barsh 1998). If after this screening meaningful indications for sleep disturbances are uncovered, the sleep specialist, after stepwise diagnosis and conferring with other specialists, can establish in the sleep laboratory an exact diagnosis and therapeutic course. The sleep structure will be characterized into sleep onset, light sleep, deep sleep and REM sleep phases. It is essential to establish whether or not the required 3-4 deep sleep phases do occur in order to allow the body to adequately regenerate itself. People who experience arousals, for example, due to tongue base obstruction with co-occurring blood hypercapnia, are unable to enter into deep relaxation and feel exhausted and sleep deprived the following morning. Important parameters are the above mentioned AHI and blood oxygen saturation. REM phases can be established using electrooculograms and other tools to measure dream state and higher brain activity. Chin and leg muscular activity can be ascertained in order to identify, for example, Restless Leg Syndrome. This neurological disease leads to arousals similar to those seen in sleep disturbance profiles and can influence daytime wakefulness. Respiratory performance can be ascertained with CO₂ sensors on the mouth or nose and dilation band measurements over the chest and abdomen. The identification of breath interruptions without measurable respiration movements indicates a central apnea that, among other things, can have a cardiovascular or neurological origin. The physiological sequelae of sleep apnea can also be monitored. Reduction of blood oxygen saturation can be measured by pulseoxymetry and the electrocardiogram can be used in cases of cardiac symptoms. In order to maintain the focus of this article, several cases of sleep disturbances that can be diagnosed in a sleep lab have been excluded. We are interested mainly in snoring and other obstructive sleep disordered breathing that can be treated by dental professionals.

Sleep Disordered Breathing and Craniomandibular Dysfunction

It is of utmost importance that future research on sleep disturbances be geared towards a better understanding of nightly parafunctions such as teeth grinding and teeth clenching given that studies have shown that patients who wear a lower jaw protrusion bar have fewer arousals and more deep sleep phases. In addition, the frequency and intensity of bruxism was reduced (Lowe 1999). A high co-morbidity also exists between craniomandibular dysfunction (CMD) and sleep disturbed breathing that can be completely managed if noted beforehand (Williamson 2005). It is also known that mouth space development in children leads to mouth breathing and a predisposition towards the development of CMD. Obstructive sleep disturbances are contingent upon the narrowed mouth relationship (Balters 1985, Mayer-Brix 1991, Poets 1991). Evidence based data are not yet available, however, it will be all the more important for the prophylaxis of obstructive sleep disturbances once diagnosed, and subsequent therapeutic initiatives in children for the improvement of nose breathing and malformation of the jaw using adequate functional orthopedic tools (Carvalho 2008).

The Treatment of Sleep Disordered Breathing

According to interdisciplinary diagnostics, SDB therapy can be summarized by 5 points:

1. Firstly, improvement in breathing should be attempted through changes in the patient's behavior at different levels. This approach is very effective in responsible patient groups (Shneerson 2008). Weight reduction is also very important since a subsequent reduction in pharyngeal fatty tissue frees up the airways. An interesting initiative is the habituation to a sideways sleeping position either by using specifically manufactured or individually prepared supine position prevention vests. Patients who suffer from SDB in the supine position could benefit in particular from this approach. Better stress management, nicotine and alcohol intake reduction are also important as is also the limitation of sedatives, psychoactive drugs and muscle relaxers.
2. Pharmacotherapy does not provide clear evidence for successful treatment in SDB (Smith 2008). Nasal sprays can make nose breathing easier and Theophylline is being tried as a possible agent to reduce the frequency of interruptions in breathing.
3. Different surgical approaches are being considered. The resectioning of hyperplastic structures such as the tonsils or polyps in children is under discussion (Lim 2008). In contrast Uvulopalatopharyngoplasty (UVPPP), the surgical removal of the soft palate is evermore controversial and is currently carried out less frequently. Another type of radical therapy, the bimaxillary surgical anterior repositioning of the jaw, in marked retrognathia is indicated only in certain cases (Maurer 1998, Sundaram 2008).
4. According to strong scientific evidence, high pressure breathing through a mask (CPAP – Continuous Positive Air Pressure) at night time inhibits pharyngeal obstruction of the airways (Giles 2008). This method remains the „Gold Standard“ in extreme cases of apnea, but due to its practical disadvantages and psychological impact is not always a plausible intervention (Fietze 1993, Maurer 1998). The patient who is able to accept the device shows a significant improvement in symptoms and quality of life.
5. Treatment with lower jaw protrusion devices belongs in the hands of dentists and can provide equally good results particularly if the efficiency with CPAP is inadequate (Randerath 2007, Giles 2008, Lim 2007). Before beginning

therapeutic intervention of sleep disorders, clinical and radiological diagnostics as well as a detailed characterization of sleep anamnesis should be carried out. The number, placement, and degree of looseness of the teeth used to hold the device in place must also be evaluated. In obstructive sleep disorders Class II Division 1 and Class II Division 2 are frequently assumed such that patients with a horizontal growth pattern look significantly better with IPS than vertical growth types (Cistulli 2001). There are numerous repositioning tools on the market and the most effective are the bimaxillary UPS that help in 50% of cases. The protrusion of the lower jaw widens the posterior airway space (PAS) in healthy and apnea prone patients by up to 56% and is particularly effective in micro- and retrogenia patients (Jamieson 1986, Kuna 1991, Mezzanotte 1992, Schmidt-Novara 1995). In this way the solutions for the airway space involve appearance and not only mechanical aspects, and subsequent changes in the mouth and throat muscles also lead to increase tone.

Dental Therapy Indications for Sleep Disordered Breathing

The statement report put forth by The German Society for Dental Medicine (DGZS) (www.dgzs.de) and made public on June 1, 2007 in the journal *Sleep and Breathing* turned out to be the most important aid for the dental practitioner dealing in sleep disordered breathing therapy. The elements of the scientific assessment and international guidelines suggest the use of the protrusion bar in the management of SDB as follows:

1. As initial therapy in
 - Primary snoring
 - Upper Airway Resistance Syndrome
 - Low to mid grade obstructive sleep apnea (AHI around 25/h) with negligible clinical symptoms, adequate intraoral anchoring possibilities, and a Body Mass Index (BMI) of about 30 kg/m²
2. In SDB with AHI over 25/h, protrusion bars can be used only after prior alternative therapy trials with nCPAP have been attempted.
3. Independent of severity of SDB in cases of nCPAP refusal and non-compliance
4. A specific dental, oral and functional diagnosis has to be carried out before the insertion of a protrusion bar.
5. Previous evaluation by an established inter- and intradisciplinary treatment program, particularly in the face of specialized diagnoses and interconnected therapy.
6. Procedures should be carried out by a doctor of dentistry licensed in the area of sleep medicine.

Contraindications for the lower jaw protrusion bar

The contraindications for this intraoral tool are obvious snoring or sleep related obstruction that is not caused by the tongue, for example, nasal position change or vibrations through the soft palate. An insufficient number of existing teeth can hinder the fastening of the tool, however, bars without strong anchoring to one another are frequently still inserted. A therapy trial with implants that fasten the apparatus in the presence of tooth loss can be taken under consideration; however, the protrusion must be carefully titrated. Myofacial pain or arthralgia/arthritis within the scope of CMD can aggravate the protrusion of the lower jaw. Frequently the condition must be handled by traditional occlusion bars or another device, or else the UPS can be worn alternately with these bars. Snoring or light cases of OSAS can frequently be mitigated with a simple bite holder so that treatment is possible even in cases of CMD. Incompatibility with synthetic material or metallic components as well as problems with compliance also obviously contraindicate the insertion of this intraoral device.

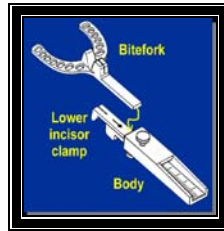
Side Effects of Dental Protrusion Therapy







The dentist must consider the side effects of protrusion therapy in terms of the indications for use. Dryness of the mouth or excessive saliva production can be somewhat annoying in the beginning. In these cases it is sensible to set up a habituation regimen in which the device is used over the course of several weeks in blocks of a few hours during the day and/or night. The duration of use is slowly lengthened followed by increased nighttime use. The protrusion movement can, as already mentioned, produce problems in the jaw joint and muscle. In this case a careful habituation process is advisable and the patient must also be forewarned of this potential problem. If the teeth do not match up in the morning, as a rule it helps to bite down hard or to push the protrusion back lightly. Compliance with this type of therapy is more unfavorable relative to traditional therapy with occlusion bars. This fact, however, does not consider the clinical picture, particularly because these individuals are chronically tired, sleep poorly and are unwilling to wear an uncomfortable device in their mouths. Closely spaced, regular check ups of the device are in any case advisable to permit the correction of malfunctions and ill fit in a timely fashion.

Bite Reading in Lower Jaw Protrusion Bars III. 1

The bite reading for the manufacture of the UPS can be accomplished with different tools. In general it is necessary to establish the reading that the patient favors in terms of the placement of the articulator. There will be individual differences in fastening security. In the author's practice the bite space is determined with a George© bite fork with which the protrusion can be precisely measured and placed. Next, the bite fork is tried on the upper and lower incisors and fixed. Maximum retrusion and protrusion is then marked on the millimeter scale. 50-60% of the span is marked and fixed with fastening screws. Finally, the upper and lower portions of the bitefork are filled with a bitespace material (e.g., Futar D Occlusion©) and the patient bites down in this position. In the event that a many sided occlusion is discovered, lateral reading material must be attached or pressed in through the side piece. After hardening, the bite fork can be removed and can be sent to the lab with the Model/Impression without a carrier. After several attempts with intra and extra oral stick supported reading systems such as T.E.N.S. the authors have determined that the procedure is easy, safe, fast, and good value.

III.1

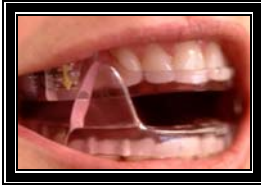



		
Fitting of Bitefork on Upper Front Teeth	Fitting of Displacement Bar Bite Down Bar on Lower Front Teeth	Bite Reading using George With Max. Inscription Protrusion and Retrusion
		
50-60% of the Protrusion is measured and fastened With Adjusting Screws	Bite registration using Georges with Futar D Occlusion© For example	Leave to harden and Dispatch of Bitefork with the Model/Impression

The "SomnoDent"-Bar© III.2

Given the wide range of UPS on the market one should take a careful look at the SomnoDent-Bar. According to the DGZS (German Society for Dental Sleep Medicine), DGSM (German Society for Sleep Research and Sleep Medicine), AASM (American Academy of Sleep Medicine) und AADSM (American Academy of Dental Sleep Medicine) the device can be considered a bimaxillary titration bar tool. This tool permits the adjustment of protrusion by lateral pushing or by the patient to 5mm, which for the patient wearing the bars translates into plenty of latitude for the patient and permits them to handle issues by phone. The complete encirclement of the tooth group and teeth minimizes the danger of orthopedic jaw movement and periodontal overload. The horizontal overbite makes a sideways pushing movement possible, relief from jaw joint, chewing and head musculature pain and notably reduces bruxism (Landry 2006). The many degrees of freedom also helps avoid feelings of being locked up and promotes a muscle relaxing effect. In contrast to many other devices, this UPS produces no loss of strength since the two bars are not directly joined but rather only grab hold of one another only when the mouth is closed. This quality proves particularly successful in patients with difficult retention ratios due to short or conical teeth, and in patients with removable dentures or with few remaining teeth. The lateral wings must be built in a relatively stable manner that fits over the face. A more graceful shape for future models would be desirable. It is pleasant to wear the Somnodent soft version, which is soft on the inside and hard on the outside.

Abb.2

	
The side wings of the Somnodent bars prevent a drop in the lower jaw.	10x activated on both sides in direction of action = 1mm Protrusion, max. 5mm possible

Summary

It is important to view Sleep Disordered Breathing from an interdisciplinary approach and to take into consideration that patients with this condition will have to be managed for their whole lives. Dental medicine, like so many other specialties, must be integrated into medicine as a whole and can no longer be considered as some separate entity. Whether in diagnosis or therapy dental medicine can play a stepwise, progressive role on a team. A requisite for this cooperative work is a functional network consisting of therapists from the different sleep medicine disciplines such as neurology, pulmonology, internal medicine, dental medicine, HNO psychology and others. Regular meetings in quality control circles, job circles, workshops and symposia are essential in order to exchange information regularly as well as to validate the disciplines and make possible continued improvement of treatment quality. Treatment of SDB with lower jaw protrusion bars has in the last few years has been shown to be effective, beautifying and a rational therapeutic approach. It also stands up to scientific evidence. Among the many effective UPS the Somnodent bars are presented here because of its outstanding compliance rate due its lack of restriction in mouth opening, comfortable fit and longer life.

Bibliography

- ASDA: American Sleep Disorders Association. EEG arousal: Scoring rules and examples. *Sleep* 1992;15:174-84
- Balters W.: Leitfaden der Bionator-Technik. Zusammengestellt und herausgegeben von Fritz Geuer, 1985, Waldbröl. Labor für Kieferorthopädie, Büscherhof 10 A, D-51545 Waldbröl
- Barsh LI : Dentistry's role in the recognition and the treatment of sleep-breathing disorders: The need for cooperation with the medical community. *CDA Journal*, 26;1998:591-598
- Cassel W, Ploch T: Schlafbezogene Atmungsstörungen: Unfallgefahr als psychosozialer Risikofaktor. *Schlaf, Gesundheit, Leistungsfähigkeit*. Eds. Hecht/Engfer/Peter/Poppei. Springer Verlag, Berlin Heidelberg 1993
- Cistulli PA, Gotsopoulos H, Sullivan CD: Relationship between craniofacial abnormalities and sleep-disordered breathing in Marfan Syndrome. *Chest* 2001;120:1455-60
- Fietze I et al.: Befunde bei Patienten mit obstruktivem Schlafapnoesyndrom unter nCPAP-Therapie. *Pneumologie* 47;1993: 170-174
- Giles TL, Lasserson TJ, Smith BJ, White J, Wright J, Cates CJ: Continuous positive airways pressure for obstructive sleep apnoea in adults. *Cochrane Database of Systematic Reviews* 2008
- Guilleminault C, Kim YD, Stoohs R. Upper airway resistance syndrome. *Oral and Maxillofacial Surgery Clinics of North America* 1995. 7;243-56
- Guilleminault C, Winkle R, Korobkin R, Simmons B. Children an nocturnal snoring: evaluation of the effects of sleep related respiratory resistive load and daytime functioning. *Eur J Pediatr* 1982;139:165-71
- ICSD: International classification of sleep disorders. Diagnostic and coding manual 342. Allen Press, Minnesota, 1997
- Jamieson A et al.: Obstructive sleep apnea patients have craniomandibular abnormalities. *Sleep* 1986;9:469-477
- Konnermann M, Sanner B, Sturm A: Schlafbezogene Atmungsstörungen und assoziierte kardiovaskuläre Erkrankungen. *Medizinische Klinik* 90 (1995): 480-485
- Kuna ST, Sant' Ambrogio G: Pathophysiology of upper airway closure during sleep. *JAMA*, Vol 266,1991: 1384-1388
- Landry ML, Rompré PH, Manzini C, Guitard F, de Grandmont P, Lavigne GJ: Reduction of sleep bruxism using a mandibular advancement device: an experimental controlled study. *Int J Prosthodont*. 2006 Nov-Dec;19(6):549-56
- Lim J, Lasserson TJ, Fleetham J, Wright J: Oral appliances for obstructive sleep apnoea
Year: *Cochrane Database of Systematic Reviews* 2006
- Lowe A: Oral appliance therapy, bruxism, vertical Dimension & tooth movement in the treatment of sleep disordered breathing. Annual meeting of SDDS. Orlando, USA, 18.6.1999
- Maurer JT, Hörmann K: Diagnostik und Therapie von schlafbezogenen Atmungsstörungen. *HNO*, 12-1998, 46:958-968
- Mayer-Brix J et al.: Schnarchen und schlafbezogene Atmungsstörungen bei Kindern- Klinik, Differentialdiagnosen und Indikationen zur Adenotonsillektomie. *Archives of Oto-Rhino-Laryngology. Suppl.* 1991/1:80-110
- Mezzanotte WS et al.: Waking genioglossal electromyogram in sleep apnea patients versus normal controls (a neuromuscular compensatory mechanism). *The Journal of Clinical Investigation*, 89, 1992:1571-1579
- Peter JH, Faust M: Schlafbezogene Atmungsstörungen: Von den Syndromen zum Risikofaktor. *Pneumologie* 45, Mai 1991:195-312
- Peters AJ et al.: Prognostisch relevante Parameter bei Patienten mit koronarer Herzkrankheit, arterieller Hypertonie und schlafbezogenen Atmungsstörungen. *Pneumologie* 6;1997: 1-6
- Poets CF, Paditz E: Obstruktives Schlaf-Apnoe-Syndrom. *Monatsschr Kinderheilkd* 1998, 146:826-836
- Randerath W, Bauer M, Blau A, Fietze I, Galetke W, Hein H, Maurer JT, Orth M, Rasche K, Rühle KH, Sanner B, Stuck BA, Verse T und Task Force der Arbeitsgruppe Apnoe der DGSM: Stellenwert der Nicht-nCPAP-Verfahren in der Therapie des obstruktiven Schlafapnoe-Syndroms. *Somnologie*, 2007, 67-98
- Rasche K, Schultze-Werninghaus G: Schlafapnoe und Unfallneigung. *Kompaß* 105, 10/1995
- Schmidt-Novara WW, et al.: Oral appliances for the treatment of snoring and obstructive sleep apnea: A review. *Sleep* 18: 501-510,1995
- Shneerson J, Wright J: Lifestyle modification for obstructive sleep apnoea. *Cochrane Database of Systematic Reviews* 2008
- Lim J, McKean M: Adenotonsillectomy for obstructive sleep apnoea in children. *Cochrane Database of Systematic Reviews* 2008
- Smith I, Lasserson TJ, Wright J: Drug therapy for obstructive sleep apnoea in adults. *Cochrane Database of Systematic Reviews* 2008
- Sundaram S, Lim J, Lasserson TJ: Surgery for obstructive sleep apnoea. *Cochrane Database of Systematic Reviews* 2008
- Waller PC, Bhopal RS: Is snoring a cause of vascular disease? *An Epidemiological Review. The Lancet*, 21; 1989: 143-146
- Williamson EH: Temporomandibular dysfunction and repositioning splint therapy. *Prog Orthod*. 2005;6(2):206-13



Dr. Horst Kares

Year of Birth 1959

1977: German-French High School Diploma Saarbrücken

1984: Doctor of Surgical Dentistry University of Nancy/Metz, France

1985 Residency in Saarbrücken

1994 Private Practice in Dentistry with focused activity in teaching, pain therapy and sleep medicine

Numerous domestic and international presentations such as publications on CMD, Orofacial pain and dental sleep medicine

Master of International College of Craniomandibular Orthopedics – Germany section - ICCMO

Qualified Member of the German Society for Dental Sleep Medicine DGZS

Qualified Member of the German Society for Whole Health Dental Medicine GZM

Member of the Mouth and Face pain job circle of the German Society for the study of pain

Member and Coordinator of the Saarbrück Sleep Medicine Quality Circle

Qualified Member of the SomnoDent Academy

SomnoDent AG

Seefeldstrasse 69

8008 Zürich

Schweiz

Tel: +41 43 4883728

Fax: +41 43 4883500

Mail: info@somnodent.com

Web: www.somnodent.com